ARTICLE

Efficacy of Duct Tape vs Placebo in the Treatment of Verruca Vulgaris (Warts) in Primary School Children

Marloes de Haen, MD; Marcus G. Spigt, PhD; Caro J. T. van Uden, PhD; Pierre van Neer, MD; Frans J. M. Feron, MD; André Knottnerus, PhD

Objective: To determine the efficacy of duct tape compared with placebo in the treatment of verruca vulgaris.

Design and Setting: A randomized placebo-controlled trial in 3 primary schools in Maastricht, the Netherlands.

Participants: One hundred three children aged 4 to 12 years with verruca vulgaris.

Interventions: Duct tape applied to the wart or placebo, a corn pad (protection ring for clavi), applied around the wart for 1 night a week. Both treatments were applied for a period of 6 weeks. Patients were blinded to the hypothesis of the study.

Main Outcome Measurement: Complete resolution of the treated wart.

Results: After 6 weeks, the wart had disappeared in 16% of the children in the duct tape group compared with 6% in the placebo group ($P=.12$). The estimated effect of duct tape compared with placebo on diameter reduction of the treated wart was 1.0 mm ($P=.02$, 95% confidence interval, −1.7 to −0.1). After 6 weeks, in 7 children (21%) in the duct tape group, a surrounding wart had disappeared compared with 9 children (27%) in the placebo group ($P=.79$). Fifteen percent of the children in the duct tape group reported adverse effects such as erythema, eczema, and wounds compared with 0 in the placebo group ($P=.14$).

Conclusion: In a 6-week trial, duct tape had a modest but nonsignificant effect on wart resolution and diameter reduction when compared with placebo in a cohort of primary school children.

Arch Pediatr Adolesc Med. 2006;160:1121-1125

Author Affiliations: Departments of General Practice (Drs de Haen, Spigt, and Knottnerus) and Dermatology (Dr van Neer), Maastricht University, Maastricht, the Netherlands; Department of Integrated Care, University Hospital Maastricht, Maastricht (Dr van Uden); and Youth Health Care Division, Regional Public Health Institute, Maastricht (Dr Feron).

THREE PERCENT TO 20% OF school-aged children have warts.[1] Warts (verruca vulgaris) are skin infections caused by the human papillomavirus. Although they are harmless and usually self-limiting, they can stigmatize a child or cause physical discomfort, for example, in the case of plantar warts.[2] Many therapies have been developed for the treatment of warts, but most of these treatments have adverse effects such as pain and irritation or need to be applied for a long time. In a Cochrane review of 50 wart therapy trials, sufficient evidence was found only for the efficacy of salicylic acid.[3]

In the department of general practice at Maastricht University, general practitioners can propose new topics for research by using the "idea box." In January 2005, a proposal was submitted about researching the effects of duct tape on warts. Duct tape is a strong sticking tape normally used by do-it-yourselfers for small industrial applications. To our knowledge, only 1 study has been published on duct tape treatment for warts. In this study, Focht et al[4] treated warts with either cryotherapy or duct tape occlusion therapy. After 2 months, 85% in the duct tape arm vs 60% in the cryotherapy arm had complete resolution of their warts. However, this result has been debated because of the small number of subjects (n=61), the large loss to follow-up (16%), the method of application of the cryotherapy, and the lack of a placebo arm.[5]

See also page 1126

Considering the serious discomfort of cryotherapy and the awkwardness of applying salicylic acid for a long time, simply applying tape would be a cheap and helpful alternative, especially in children. However, according to the critics on Focht et al,[4] a blinded randomized control trial comparison of duct tape with placebo and/or salicylate is first indicated.

METHODS

We performed a randomized controlled trial in which we treated warts in primary school children with either duct tape or placebo for a

Downloaded from www.archpediatrics.com on January 26, 2009
©2006 American Medical Association. All rights reserved.

period of 6 weeks. Children treated their warts at home, and 1 researcher (M.D.) performed the outcome measurements at school. At the baseline measurement, she counted the total number of warts and measured the diameter of the warts. She also decided which wart would be treated. Only 1 wart (usually the largest; otherwise, 1 surrounded by other warts) was treated in each child. To evaluate the effect of the tape on the primary and surrounding warts, the diameters of a maximum of 5 warts were measured. To blind the assessor, a second researcher (M.S.), who was not involved in the follow-up measurements, applied the first treatment. He telephoned the central randomization office that assigned the intervention and kept the randomization key. Randomization was performed in blocks of 10 stratified in 2 groups (single or multiple warts).

POWER CALCULATION

In a review about wart therapies, it was estimated that approximately 30% of warts disappear after 10 weeks of placebo therapy.[3] To provide evidence for a minimal difference of 30% against placebo with a power of 80%, an α of .05, and 2-tailed statistical testing, we calculated that we would need 39 children in each group. Taking into account probable loss to follow-up, the aimed study population was set at 100 children.

PARTICIPANTS

In cooperation with the Youth Health Care Division of the Regional Public Health Institute (Maastricht, the Netherlands), we approached children of 3 primary schools to take part in this study. Every child in these 3 schools received a letter to inform the parents about the trial. A special "child folder" was added with information about the study written at a child's reading level. Children aged 4 to 12 years with verruca vulgaris were included. Exclusion criteria were immune suppression, bandage allergy, skin diseases in the area surrounding the wart, and warts on the face or anogenital region. Parents were asked to fill in a written questionnaire about the history of the wart and the inclusion and exclusion criteria. The informed consent form had to be signed by both parents. If a child showed any resistance to the measurements or treatments during the study, no further investigations were performed. The ethical review board of the University Hospital Maastricht and Maastricht University approved the research protocol and the informed consent procedure.

INTERVENTIONS

Children treated their warts at home. They received written instruction, including pictures, on how to apply the duct tape or the placebo. Both interventions had to be applied for their respective periods for 6 weeks. The intervention group received a duct tape that was fabricated by 3M (Leiden, the Netherlands). To minimize the risk that people would recognize the duct tape, we used the transparent version. In addition, we figured that the transparent version would be more cosmetic. The tape was removed from the original roll and pasted on sticker paper. The duct tape group received 10 strips of duct tape, which the participants had to cut to the size of the wart. The tape had to remain on the wart for 7 days. If the tape fell off, the parents had to apply a new piece of tape on the wart. In accordance with the study by Focht et al[4], at the evening of the seventh day, the parents had to remove the tape, soak the wart for 5 minutes in warm water, and rub the wart gently with a pumice stone. On that night, the wart was left untreated, and the next day the participants started the duct tape application again.

The placebo group received 10 pieces of placebo, a protection ring for clavi, which they had to apply around the wart. The clavi rings were also pasted on sticker paper so that the brand name was unknown. Because this ring had an open center, the wart itself was left clear. To avoid any influence of the glue in the ring, the children were instructed to apply the placebo only 1 night per week. As in the duct tape group, they were asked to soak and rub the wart with a pumice stone once a week.

Because it is unknown how duct tape achieves its possible effect, it was impossible to fabricate a placebo copy. Therefore, participants were not informed about the specific treatment investigated in this study. We mentioned that they would be allocated in a random fashion to 2 interventions and that they would receive "some kind of tape" for their wart. They were also informed that it was possible that they would receive an ineffective intervention for a period of 6 weeks. All participants were fully informed about the study aim after study termination.

MEASUREMENTS AND OUTCOME PARAMETERS

Outcome measurements were performed at school at 0, 2, 4, and 6 weeks of treatment. One assessor (M.D.), who was aware of the study hypothesis, examined all children. To blind the assessor, parents were asked to remove the tape before each measurement. The location of the wart was defined by a picture and written description. At each measurement, the total number of warts was counted and the presence of the treated wart was checked. In addition, the sizes of the primary wart and a maximum of 4 surrounding warts were measured. The diameters of the warts were measured in tenth of millimeters using a sliding caliper. The primary outcome measurement of this study was complete resolution of the treated wart. Secondary outcome measurements were disappearance of other warts and reduction in diameter of the treated wart and surrounding warts.

In addition to these outcome measurements, we assessed the success of blinding. First, to check the success of our attempt to blind them for the hypothesis for this study, we asked parents about their expectations about the efficacy of the tape in the first week. Second, the assessor noted at each effect measurement whether she was blinded to the treatment that was used. Finally, to monitor the applicability, adverse effects, use of additional therapies, and discontinuation of the treatment, parents were asked to fill in a short questionnaire at the end of the treatment period before they were unblinded to the study goals.

STATISTICAL ANALYSIS

Differences between the 2 groups in wart disappearance were analyzed using a χ^2 test. Diameter reduction was analyzed by linear regression in which the treatment was the independent variable and the baseline diameter the covariable. A P value of $<.05$ was considered statistically significant. Differences in adverse effects and differences in blinding of the patients and researcher were analyzed using χ^2 tests.

RESULTS

PATIENTS

Fourteen hundred forty children of 3 primary schools received the information about the trial (**Figure**). One hundred twenty-one children were scheduled for a baseline assessment. Two children were excluded because they were absent on the day of measurement; 16 others were excluded for reasons shown in the Figure. Finally, 103

Downloaded from www.archpediatrics.com on January 26, 2009
©2006 American Medical Association. All rights reserved.

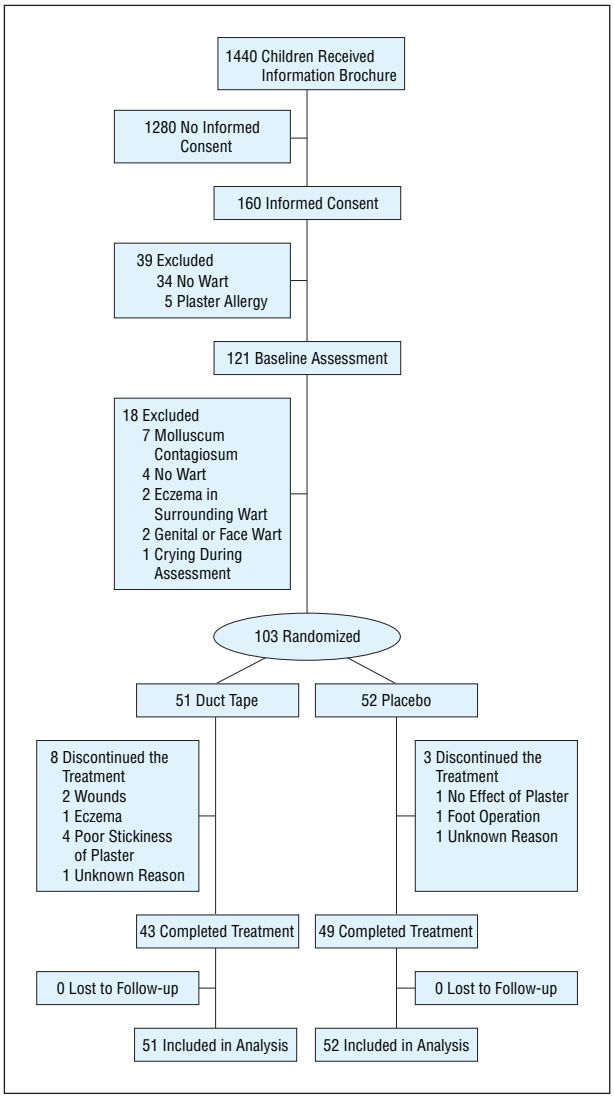

Figure. Trial profile.

children were randomized of whom 51 were assigned to the duct tape group and 52 to the placebo group. During the study, 8 children (17%) in the duct tape group stopped applying the duct tape, most of them in the first 2 weeks. One stopped for unknown reasons, 4 stopped because of the poor stickiness of the tape (eg, less than 1 hour), and 3 were advised to stop because of wounds or eczema caused by the tape. The reasons for discontinuation for 3 children in the placebo group were as follows: 1 was in the hospital because of an operation, 1 child stopped because he did not experience any effect of the treatment, and for 1 child the reason was unknown. These children stopped in the last 2 weeks. Parents of children who discontinued the treatment were asked for the reason of discontinuing and were instructed about the necessity of follow-up. These outcome measurements were included in the analysis.

BASELINE CHARACTERISTICS

Table 1 shows the baseline characteristics of the 2 treatment groups. The mean number of warts as well as the baseline size of the treated wart was comparable between the 2 groups. In the duct tape group, fewer warts were located on the finger or dorsum of the hand (22% vs 35%) and more warts were located at the toe or foot (29% vs 25%). The warts had existed longer in the duct tape group than in the placebo group (34.2 vs 38.5 weeks). Forty-seven percent in the duct tape group vs 62% in the placebo group had received prior treatment for their warts.

Table 1. Baseline Characteristics

Characteristic	Duct Tape (n = 51)	Placebo (n = 52)
Sex, %		
Male	45	52
Age, mean ± SD (range), y	8.2 ± 2.0 (5-12)	8.3 ± 2.0 (5-12)
Single/multiple warts, No. (%)		
Single	18 (35)	19 (37)
Multiple	33 (65)	33 (64)
Warts, mean ± SD (range), No.	3.4 ± 3.4 (1-16)	3.7 ± 4.1 (1-17)
Location of treated wart, No. (%)		
Finger/dorsum of hand	11 (22)	18 (35)
Palm of hand	3 (6)	2 (4)
Toe/dorsum of foot	15 (29)	13 (25)
Plantar part of foot	10 (20)	10 (19)
Back of heel	1 (2)	0
Other	11 (22)	9 (17)
Duration of wart, mean ± SD (range), wk	34.2 ± 33.9 (4-156)	38.5 ± 34.7 (2-156)
Prior treatment, No. (%)		
None	27 (53)	19 (37)
Cryotherapy	8 (16)	14 (27)
Salicylic acid	15 (29)	16 (31)
Other	1 (2)	2 (4)
Baseline size of treated wart mean ± SD (range), mm	4.6 ± 2.3 (1.8-13.5)	4.4 ± 1.7 (2.1-10.0)

TREATMENT OUTCOME

Complete resolution of the treated wart was seen in only a few children. The first resolution in both the duct tape and placebo groups was noted after 4 weeks. At the end of the study, after 6 weeks, the warts of 8 children (16%) in the duct tape group and the warts of 3 children (6%) in the placebo group had disappeared (**Table 2**), resulting in a number needed to treat of 10 (95% confidence interval, 5 to ∞). This difference was not statistically significant.

In the duct tape group, there was a diameter reduction of 27% (from a mean of 4.6 mm to 3.4 mm) after 6 weeks. In the placebo group, this was 9% (from 4.4 mm to 4.0 mm). When adjusted for the baseline diameter, this resulted in a statistically significant difference in diameter reduction of 1.0 mm between the 2 groups ($P = .008$).

The duct tape did not seem to have any effect on surrounding warts. After 6 weeks, in only 7 children (21%) in the duct tape group a surrounding wart had disappeared compared with 9 children (27%) in the placebo group ($P = .79$) (Table 2), resulting in a number needed

Downloaded from www.archpediatrics.com on January 26, 2009
©2006 American Medical Association. All rights reserved.

Table 2. Outcomes From 6 Weeks of Treatment With Duct Tape

Effect Parameter	Duct Tape	Placebo	*P* Value
Effects on Treated Wart			
Patients, No.	51	52	
Complete resolution			
2 wk, No.	0	0	
4 wk, No.	5	3	
6 wk, No. (%)	8 (16)	3 (6)	.12
Diameter of wart (range), mm			
0 wk	4.6 (1.8-13.5)	4.4 (2.1-10.0)	
2 wk	4.3 (1.6-15.7)	4.2 (1.4-9.1)	
4 wk	3.8 (0-22.2)	3.9 (0-10.4)	
6 wk	3.4 (0-18.4)	4.0 (0-11.2)	
Diameter reduction after 6 wk, %†	–27	–9	.02
Effect on Surrounding Warts*			
Patients, No.	33	33	
Complete resolution of at least 1 surrounding wart			
2 wk, No.	4	2	
4 wk, No.	8	7	
6 wk, No. (%)	7 (21)	9 (27)	.79
Diameter of warts (range), mm			
0 wk	3.2 (1.7-5.8)	3.0 (1.7-6.0)	
2 wk	3.2 (0-10.8)	3.0 (1.0-6.6)	
4 wk	2.9 (0-6.2)	2.7 (0-6.2)	
6 wk	3.0 (0-5.6)	2.6 (0-6.8)	
Diameter reduction after 6 wk, %‡	–21	–27	.22

*Only children with multiple warts are included in this analysis.
†The calculated difference between the 2 groups adjusted for baseline size, location of the wart, previous treatment, and duration of the wart was –1.0 mm (95% confidence interval, –1.7 to –0.1).
‡The calculated difference between the 2 groups adjusted for baseline size, previous treatment, and duration of the wart was 0.4 mm (95% confidence interval, –0.2 to 1.0).

to harm of 17 (95% confidence interval, 4 to ∞). There was no difference in diameter reduction of surrounding warts between the 2 groups.

Only 19% of the duct tape group judged the stickiness of the tape as good (**Table 3**). Both groups used additional fixation material (32% vs 33%). Seven children (15%) in the duct tape group showed a skin reaction caused by the duct tape, mostly erythema ($P=.14$) None of the participants in the placebo group showed any skin reaction. Both groups reported pain and/or bleeding caused by the pumice stone. None of the participants used other wart therapies during the study.

The prior expectations of the participants toward the efficacy of their treatment was rather low but comparable between the 2 study groups ($P=.38$). The duct tape scored 5.6 on a scale from 0 to 10 and the placebo scored 5.1 (**Table 4**). During the measurements, the assessor recorded whether she knew which kind of treatment had been applied when she performed the measurements. It turned out that she was blinded in 69% of the measurements in the duct tape group. In the placebo group, this was significantly higher: 83% ($P=.03$) (Table 4).

Table 3. Applicability and Adverse Effects*

Effect Parameter	Duct Tape (n = 47)†	Placebo (n = 52)	*P* Value
Stickiness of the plaster			
Good	9 (19)	38 (73)	<.001
Moderate	20 (43)	4 (8)	
Bad	18 (38)	10 (19)	
Use of extra fixation material	15 (32)	17 (33)	.93
Skin reaction caused by the tape			
None	40 (85)	52 (100)	.14
Erythema	3 (6)		
Itching	1 (2)		
Eczema	1 (2)		
Bleeding	1 (2)		
Other	1 (2)		
Skin reaction caused by the pumice stone			
None	28 (60)	38 (75)	.24
Pain	11 (23)	9 (18)	
Bleeding	8 (17)	4 (8)	
Reason for discontinuing the treatment			
Poor stickiness	4 (9)		.75
Wounds	2 (4)		
Eczema	1 (2)		
Other	0	2 (4)	
Unknown reason	1 (2)	1 (2)	

*All values other than *P* values are numbers (percentages).
†Number is less because of missing values.

COMMENT

Our study shows that duct tape has no significantly better effect on the resolution of warts than placebo. We found an effect on diameter reduction of 27%. The duct tape did not seem to have any effect on surrounding warts. The majority (81%) of the children reported that the duct tape would not stick and 15% reported adverse effects such as erythema. This is inconsistent with the previously reported positive results observed by Focht et al.[4]

An important finding in our study was the applicability and adverse effects of the duct tape. In the study by Focht et al, only "a minimal amount of local irritation and erythema and difficulty for some patients in keeping the tape on" was mentioned. In our study, the latter turned out to be highly important. Only 19% of the duct tape group judged the stickiness of the tape as good; 32% used extra fixation material. In our view, this is crucial because it makes the treatment a bothersome rather than a feasible alternative for other wart therapies. In addition, 15% of the children in the duct tape group showed adverse effects varying from erythema to eczema and small wounds.

DIFFERENCES BETWEEN THE 2 STUDIES

How can we explain the differences in effects between our study and that of Focht et al?[4] Maybe the high efficacy of duct tape in the study by Focht et al could be explained by their follow-up. Part of the follow-up in that study was performed by telephone. This can result in a

Downloaded from www.archpediatrics.com on January 26, 2009
©2006 American Medical Association. All rights reserved.

more positive judgment about wart resolution by the parents, especially if the parents were not blinded to the objective of the study (ie, to investigate the effects of duct tape).

The poor stickiness of the duct tape may have negatively influenced our observed effects. However, we emphasized to parents the importance of keeping the tape on, and parents said they tried their utmost to comply with this instruction. For that reason, we do not think that the short periods the wart was uncovered can explain the low efficacy of the duct tape. In addition, we analyzed whether children who had complete resolution of the treated wart judged the tape as sticking well. If the effect of the duct tape would be so low because of the bad stickiness, one would expect that the children who had complete resolution of their wart had a better sticking tape, which turned out not to be the case. Only 1 of 8 children in the duct tape group who had complete resolution judged the tape as sticking well. However, it is possible that Focht et al[4] used a different and maybe more effective kind of duct tape. We do not know which kind of duct tape was used in their study. We used the transparent version of duct tape produced by 3M. The producer of the tape guaranteed this tape had the same stickiness as the well-known silver variant.

Finally, the overall low effectiveness of both interventions in our study is surprising.

Considering the estimated placebo effect of 30% in 10 weeks, the observed 6% effect in our placebo group was small. One explanation could be that in both groups, a part of the children had already used other wart therapies, which could result in more resistant warts. Besides that, the effects in a placebo group are the result of many variables, such as natural course of the disease, regression to the mean, cointerventions, placebo effects, and probably many other unknown variables. All these different variables can sum up to a large effect in the placebo group or, in our case, can explain a small effect. Hence, both the duct tape and the placebo could do better in other studies, but it is crucial that in our study the duct tape was not more effective than placebo although it did have more adverse effects. Therefore, we do not think that, when subjected to firm investigation, the duct tape would do much better than placebo or better than other effective interventions.

FUTURE RESEARCH

The effect on diameter reduction could be a reason for further investigation, although we do not think that this is of clinical importance. Nevertheless, we advise taking the following suggestions into account when studying duct tape any further. First, it is important to use a very sticky tape. Second, a longer follow-up period is needed to observe any effect of the duct tape. Finally, we suggest not using a pumice stone. We used the pumice stone to make our study comparable with that of Focht et al[4], but the reasons to use the pumice stone besides the duct tape are unclear. Many children in our study experienced scrubbing with the pumice stone as very unpleasant, and bleeding of the wart (caused by the pumice stone) could lead to spreading of the wart virus.

Table 4. Success of Blinding Patients and Researcher

Measure	Duct Tape (n = 51)	Placebo (n = 52)	*P* Value
Expectation rating by the patient about the efficacy of the treatment after 1 week of treatment, mean ± SD (range, 1-10)*	5.6 ± 2.3	5.1 ± 2.8	.38
Blinding of the researcher during the outcome measurements, %	69	83	.03

*A score of 10 is the most favorable score.

CONCLUSION

In this 6-week study, duct tape was no more effective than placebo. The duct tape was difficult to use because of poor stickiness, and it caused a skin reaction in 15% of the children. Further research with longer follow-up would only be useful with a tape that is better sticking.

Accepted for Publication: July 4, 2006.
Correspondence: Marcus G. Spigt, PhD, Department of General Practice, Maastricht University, PO Box 616, 6200 MD Maastricht, the Netherlands (m.spigt@hag.unimaas.nl).
Author Contributions: All authors had full access to all the data in the study and take responsibility for the integrity of the data and the accuracy of the data analysis. *Study concept and design:* de Haen, Spigt, van Uden, van Neer, and Knottnerus. *Acquisition of data:* de Haen, Spigt, and Feron. *Analysis and interpretation of data:* de Haen and Spigt. *Drafting of the manuscript:* de Haen and Spigt. *Critical revision of the manuscript for important intellectual content*: Spigt, van Uden, van Neer, Feron, and Knottnerus. *Statistical analysis:* de Haen. *Administrative, technical, and material support:* de Haen, Spigt, Feron, and Knottnerus. *Study supervision:* Spigt, van Uden, van Neer, and Knottnerus.
Financial Disclosure: None reported.

REFERENCES

1. Burns DA, Breathnach SM, Cox N, Griffiths CE. *Rook's Textbook of Dermatology*. 7th ed. Oxford, England: Blackwell Publishers; 2004.
2. van de Lisdonk EH, van den Bosch WJHM, Lagro-Janssen ALM. *Ziekten in de Huisartspraktijk*. Maarssen, the Netherlands: Elsevier; 2003.
3. Gibbs S, Harvey I, Sterling J, Stark R. Local treatments for cutaneous warts: systematic review. *BMJ*. 2002;325:461.
4. Focht DR III, Spicer C, Fairchok MP. The efficacy of duct tape vs cryotherapy in the treatment of verruca vulgaris (the common wart). *Arch Pediatr Adolesc Med*. 2002;156:971-974.
5. Ringold S, Mendoza JA, Tarini BA, Sox C. Is duct tape occlusion therapy as effective as cryotherapy for the treatment of the common wart? *Arch Pediatr Adolesc Med*. 2002;156:975-977.

Downloaded from www.archpediatrics.com on January 26, 2009
©2006 American Medical Association. All rights reserved.